

---

## On the Structure of the Dicynodont Skull

Igerna B. J. Sollas and W. J. Sollas

*Phil. Trans. R. Soc. Lond. B* 1916 **207**, 531-539  
doi: 10.1098/rstb.1916.0012

---

### Email alerting service

Receive free email alerts when new articles cite this article - sign up in the box at the top right-hand corner of the article or click [here](#)

---

To subscribe to *Phil. Trans. R. Soc. Lond. B* go to: <http://rstb.royalsocietypublishing.org/subscriptions>

---

XII. *On the Structure of the Dicynodont Skull.*By IGERNA B. J. SOLLAS and W. J. SOLLAS, *F.R.S.*

(Received December 23, 1915,—Read March 2, 1916.)

[PLATES 35 AND 36.]

We propose in this communication to supplement our previous account\* of the *Dicynodon* (*D. leoniceps?*) skull by some observations on another specimen of unknown species, for which we are indebted, through the kind offices of Dr. SMITH WOODWARD, to the generosity of the Trustees of the British Museum.

As is so commonly the case, this skull is included in a hard calcareous nodule, and thus inaccessible to systematic observation except by serial sections. It was found in the Karoo beds of South Africa.

In general form it resembles one of the narrower forms of *Dicynodon*, measuring 5.5 cm. in length, 4 cm. in vertical height at its highest point as it rests on the lower jaw, and 4 cm. in breadth where broadest—*i.e.*, at the occiput. It is not provided with teeth, and though its precise taxonomic position is unknown, it may safely be referred, as Dr. WATSON suggests, to a female *Dicynodon*—*i.e.*, *Oudenodon*.

The exterior, especially the roof, has suffered sadly from the weather—a matter of comparatively little importance, since this region is well known; the more interesting parts, such as the occiput, palate, ethmoidal and otic regions, on the other hand, are well preserved, and have afforded us some additional information.

The serial sections by which the structure of this specimen was exposed were taken transversely, and consequently the longitudinally grooved structures described in our previous paper—*viz.*, the anterior prolongation of the base of the skull and the vomer—are much better displayed than in our first specimen of *Dicynodon*, which was cut longitudinally.

*Occipital Plate and Base of Skull.*

The occipital condyle is tripartite. The foramen magnum is a vertically elongated oval. Sutures between the exoccipital, basioccipital, prootic, and opisthotic seem to be entirely wanting, all these bones forming one continuous plate, in which the supra-occipital is perhaps also included. On this interpretation a median bone which lies above the dorsal wall of the foramen magnum should be the interparietal (Plate 36, figs. 1 and 2). This bone is of somewhat curious shape. For the greater part of its length its vertical section has, roughly speaking, the form of the letter H, with a very thick cross-bar. Posteriorly the cross-bar is wanting; the two vertical laminae of bone diverge, and are applied by their outer faces to the squamosal,

\* 'Phil. Trans.,' B, vol. 204, p. 201.

ventrally they unite by a short horizontal suture with the occipital plate. Thus this curious bone rests upon the occipital bones, but only comes in contact with them along two narrow, almost linear, areas, and so forms the roof of a tunnel which is floored by the occipitals. Anteriorly this tunnel and the brain cavity communicate freely. (Section 107, Plate 35, fig. 2, and the separate model of the skull cavity, Plate 35, fig. 4.) The dorsal surface of the interparietal is excavated by a deep median channel, of which the cross-section has the form of the letter U. The front end of this bone is clasped by the posterior ends of the parietals.

The base of the skull resembles very closely that of the *Dicynodon* previously described. It is impossible to determine the presence or absence of sutures in it from the series of transverse sections on which most of our observations have been based, but in another series of sections of a similar but very imperfect skull cut somewhat obliquely to its long axis, the suture between the basi-occipital and basisphenoid is distinctly visible. The carotid canal is seen, perforating the basisphenoid, in both series of sections ; it is single.

*Squamosal* (Plate 35, figs. 1–3 ; and Plate 36, figs. 1 and 2).—The outer border of the occipital plate is formed by a narrow rim of bone, the squamosal, which is applied to the outer edge of the occipital bones and the outer surface of the divergent limbs of the interparietal. The contact with the occipital is interrupted by the well-known foramen, for which a connexion with the ear was once suggested. As we pass forwards the squamosal becomes more conspicuous, forming a broader rim in transverse section. It is produced upwards and outwards into a sharp ridge standing out from the skull ; its ventral and anterior surface is very deeply excavated for the reception of the quadrate. But this condition is limited to a few sections behind ; farther in front the outer wall of the pit holding the quadrate disappears, the inner wall\* is continued forwards for some distance, and is wedged in between the quadrate on its outer side, and the opisthotic region of the skull on its inner side. When the outer wall of the pit disappears from the sections the quadrato-jugal replaces it. The forward continuation of the squamosal to meet the jugal has not been preserved.

Separate models (Plate 1) were made on a large scale of (1) the squamosal bone ; (2) the quadrate, quadrato-jugal, and columella auris in one block ; (3) the cavities of the back of the skull and the ear-canals.

The *quadrate* (Plate 35, figs. 1–3 ; Plate 36, figs. 1 and 2) is a short massive bone which might almost be described as tri-radiate ; one branch, *a*, the largest or upper, lies in a groove, *g*, on the anterior surface of the squamosal ; a second or inner and downward branch, *b*, bears on its inner surface a facet to which the outer end of the columella auris is applied ; a third or outer branch, *c*, is suturally united by its outer surface with the quadrato-jugal. Between the second and third branches is

\* This inner wall, as Mr. GOODRICH observes, extends so far downwards, between the otic mass and the quadrate, approaching the stapes, as to suggest that it is in process of replacing the quadrate in the articulation of the lower jaw.

the deep groove which receives the large convex portion of the condyle of the lower jaw. A small inwardly directed process from the articular bone rests against the lower surface of the second branch of the quadrate, and thus forms a very small concave portion of the condyle, extending only through four sections—*i.e.*, nearly 2 mm. The *quadrato-jugal* is a laminar bone, thickened at its lower end, where it unites by suture with the quadrate. Above the junction the quadrate and quadrato-jugal recede from one another; a short distance above the junction the anterior surface of the quadrato-jugal comes in contact with the squamosal, and at a higher level its inner surface also comes in contact with that bone. Just above the junction of the quadrate and quadrato-jugal there is a passage between the quadrate on the inside, the quadrato-jugal on the outside, and the squamosal above and behind.

The *columella auris* (Plate 35, figs. 1–3; Plate 36, figs. 1 and 2) may be described as a rod-like bone expanded at both ends; though the expansions are by no means confined to the ends, but extend a short distance along the shaft towards its middle. The inner end is expanded chiefly in a horizontal plane; the outer end into a disc which plugs the *foramen ovalis*; the shaft of the columella enters this disc below the centre. The columella is not perforated.

*Roofing Bones: Parietals.*—In front of the interparietals the parietals meet each other for a short distance and then diverge, passing one on each side of the pineal foramen. Behind the foramen the parietals are very narrow but thick bones. Their upper and outer angles are produced into short horizontal processes which are continued outwards by fragmentary horizontal laminae—apparently the posterior ends of the *postorbital* bones. At the anterior end of the pineal foramen the parietals meet the *preparietal* which, at first scarcely broader than the foramen itself, immediately broadens out and lies in the middle of the roof, for a short distance bordered by the tapering ends of the parietals, and outside these by the postorbitals. As we pass forwards the postorbital bones increase in breadth, finally extending downwards to meet the jugal as the postorbital bars, which are thin laminae continuing the roof of the skull outwards and downwards, and reaching to the lower edge of the jugal, to the inner faces of which they are applied. The whole arrangement is very suggestive of the existence of a false roof to the temporal fossa, either incipient or complete, but the degree of its development is impossible to determine owing to the abraded condition of the specimen in this region.

*Frontal.*—The preparietal is bounded in front by the frontals, which are fused to form a single bone.

A considerable part of the facial bones is unfortunately worn away; the anterior end of the frontals, the nasals, the facial part of the premaxilla, being lost; the lachrymal and small prefrontals, however, are preserved.

*Bones of the Palate and Face: Premaxilla* (Plate 36, figs. 6 and 7).—The palatal portion of the premaxilla bears posteriorly a very strong median ridge, which is continued backwards between the nostrils for a short distance. This ridge extends

over half the length of the palatal surface of the bone. A pair of grooves lie one on each side of it, and receive a pair of biting ridges of the lower jaw. In front this ridge is succeeded by a deep median groove bounded by a pair of sharp ridges.

The median vertical lamina or internasal plate of the premaxilla is borne by the palatal portion of the premaxilla, and is not continued forwards, as in *Dicynodon*, to the facial portion. It extends over more than half the length of the premaxilla; in front it is a low ridge sloping up gradually till it reaches its full height just about the middle of the length of the premaxilla. Here it is bestridden by the vomer, to which we shall return presently.

The facial part of the premaxilla is unfortunately incomplete.

*Maxilla* (Plate 36, figs. 4-7).—The maxilla, as in *Dicynodon*, is a large and important bone. It forms the massive rim of the upper jaw; a downgrowth from it provides the biting edge, which in life was presumably sheathed by a horny beak. A broad shelf of the maxilla overlaps the palatal portion of the premaxilla.

In front a stout lamina of bone rises from the upper surface of the maxilla; passing backwards this lamina soon divides into two, forming the inner and outer wall of a chamber which occupies a similar position to the chamber surrounding the root of the tusk in the male *Dicynodon*; though here, tusks being absent, the chamber in its present condition is empty. The inner lamina soon becomes a low ridge, leaving a gap in the inner wall of the chamber, this wall being continued backwards by the palatine; the outer lamina is continued backwards, forming the whole length of the outer wall of the chamber. The walls of the chamber are completed by the *lachrymal*, which forms the anterior part of its roof; the *jugal*, which contributes largely to the roof and outer wall; and the *palatine*, which forms the posterior part of the inner wall and floor, as well as the inner part of its posterior wall, the outer part of which is formed by the *jugal*.

Between the lachrymal and frontal small prefrontal bones are present.

The lachrymal duct is preserved on one side of the skull (Plate 36, fig. 7, *L.d.*).

The *palatines* (Plate 36, figs. 4 and 5) are very similar to those of the *Dicynodon* previously described, and contribute to the formation of the rudimentary secondary palate. Their main portion is a more or less vertical piece of bone forming the outer wall of the nasal passages; from this an alar portion passes inwards, arching over these passages and overlapping the flanges of the vomer, while two alar portions pass outwards, one to contribute to the roof, the other to the floor of the dental chamber.

*Transverse* (Plate 36, figs. 4 and 5).—In a ventral view of the skull a part of the palatine is concealed by the transverse bone which runs over part of its ventral surface and enters at its posterior end a groove in this bone. The extreme anterior end of the transverse bone is concealed, being embedded in the maxilla for a short distance. It emerges at the surface of the maxilla at the junction of the maxilla and palatine. At its posterior end on its ventral surface the transverse bears a ridge, which is continued backwards by a ridge on the pterygoid.

*Pterygoid* (Plate 36, figs. 3 and 4).—The pterygoids consist of a pair of stout bars, converging to a junction, behind which they are continued as slender bars to the quadrate bone. Each of the stout bars is smoothly rounded on its outer side, rather flat on its inner side, the two sides meeting ventrally in the ridge just mentioned in the preceding section. The paired ridges converge to form a median ridge on the ventral surface of the mass of bone formed by the junction of the pterygoids below the cranial base. At their anterior ends the pterygoids meet the transverse bone, the palatines and the bifid end of the vomer. Whether a suture exists or not between the slender posterior bar and the central mass of the pterygoid we cannot say, because the bones are fractured in this region, making it impossible even in sections, to distinguish with certainty between sutures and cracks. On the dorsal surface of the posterior bar of the pterygoid lies the expanded base of the columella cranii, running through several sections and continued in front on to the upper surface of the base of the skull, where it lies upon the conjoined pterygoids.\*

An examination of the muscles connected with the jaw in the head of an Alligator kindly given us by the Zoological Department of the Oxford Museum, suggests that the so-called “dental chamber” is an arrangement for increasing the surface from which a powerful muscle takes its origin. In the Alligator this muscle lies in the floor of the orbit, having its origin, in front, on the maxilla, laterally on the maxilla on the outer side, and on the palatine and pterygoid and prefrontal on the inside. It is exposed to view on the palate, filling the whole of the great vacuity in the floor of the orbit. Behind the orbit it lies on the upper surface of the transverse bone, round the posterior edge of which it passes, to be inserted on the free upper edge of the angular. The surface of origin on the palatine and pterygoid is increased by their arched form. The portions of the palatines and pterygoids which lie between the orbits form on each side a somewhat flattened semi-cylinder, and meeting their fellows they thus surround an elongated chamber or bulla, which we suggest is similar in function to the dental chamber of Dicynodonts.

The vacuity in the bony floor of the orbit in the Alligator would clearly give freedom to the muscle overlying it to expand in breadth when contracting. The vacuity in the lower jaw seems to have a similar significance; it does not give passage to any other structure; but the temporalis muscle which lies against the inner surface of the jaw (posterior end of the dentary and of the outer branch of the angular) can be seen through it.

*The Median Septum*: The vomer (Plate 36, figs. 4–7) is interesting for two reasons: first, its general form strongly suggests that it had a double origin; secondly, its dorsal surface is grooved. In front for a length of 6 mm., and behind for a length of 11 mm. the vomer is bifid; throughout the intervening 22 mm. it is single but bifid or bilaminar both dorsally and ventrally, and often the ventral fork extends

\* In our account of the Dicynodon skull we seem, as Dr. WATSON has pointed out to us, to have mistaken the broadened base of the columella cranii for a separate pterygoid element hitherto unrecognised.

throughout the greater part of the height of the bone. Thus it is double for 17 mm. out of 37 mm., or not much less than one-half of its length.

At its anterior end (fig. 7) the vomer consists of two thin vertical plates of bone applied to the sides of the median vertical ridge of the premaxilla. As we pass backwards these two plates soon meet each other above the premaxilla, and fuse for a short distance (fig. 6); above the level of this union the two laminae are again free, or, to express the same fact otherwise, the dorsal border of the medial bone formed by the union of the pair of laminae is grooved. At the same time the laminae also extend farther downwards, projecting into the substance of the premaxilla, and being very closely gripped by it. From the base of the dorsal groove a delicate low median lamina of bone projects upwards. As we pass still farther backwards (fig. 5) the free edges of the groove thicken and then expand horizontally and are themselves grooved, so that the dorsal surface of the vomer now presents a pair of shallow grooves and a median deeper groove. Extensions of the palatine bones rest on the upper surface of the lateral grooves. Passing still farther backwards, the lateral expansions of the vomer become stouter and the cross-section changes to the form shown in fig. 4. The median groove ceases. The ventral edge of the vomer again presents a groove, and finally we reach the bifid posterior end, each limb of which becomes connected with the pterygoid of its side.

The median groove of the vomer receives a rod-like prolongation of the cranial base, which occupies the whole length of the groove with the exception of a short distance at its anterior end. The delicate median lamina, mentioned previously as projecting upwards from the base of the median groove, penetrates the substance of the process prolonged from the cranial base. This rod-like bone is also grooved on its dorsal surface, and receives the ventral edge of the mesethmoid, an arrangement which we have already described in *Dicynodon*: its Mammalian nature hardly needs pointing out. At the same time we cannot help being struck by the resemblance of the bones of the palate to that which is seen in the more primitive type of palate in Birds, the palate, for example, of the Ostrich, a type which, as PYCRAFT\* has shown, is repeated in the ontogenetic stages of Birds possessing a more specialised palate. The striking points of resemblance lie in the bifid posterior end of the vomer, each limb of the fork meeting the pterygoid of its side; the pterygoids approximating to each other in the middle line anteriorly, and passing at the posterior ends outwards to meet the quadrate bone; the palatines and maxillae bounding the nares. The differences, of course, are obvious. HUXLEY, in 1859, remarked on the resemblance of the palate of *Dicynodon* to that of Birds.

The *mesethmoid* (Plate 36, figs. 4, 5, and 6) is a rectangular vertical plate of bone which in its anterior region expands above into a broad horizontal plate attached to the lower surface of the frontals; in its posterior region it expands at some little

\* W. P. PYCRAFT, 'The Infancy of Animals,' London, 1912, 8vo, p. 141.

distance below the frontals into a cup-shaped part, the edges of which reach the frontal and so form a little chamber which may have lodged the olfactory lobes of the brain. Two rounded apertures at the front end of this chamber appear to have served for the exit of the olfactory nerves. The mesethmoid differs only in detail from that of the *Dicynodon* previously described. While the free ventral edge of the mesethmoid in that example lay at some distance from the groove of the base of the skull (the bone probably having had a cartilaginous continuation), in the present specimen it evidently reached the groove; it is now displaced, however, and lies beside the groove, as will be seen in the photographs. The posterior notch mentioned in our previous paper as possibly marking the exit of the optic nerves is apparently absent here.

*Lower Jaw* (Plate 36, figs. 1-7).—Two features strike us in comparing the lower jaw of this *Dicynodon* with that of *Dicynodon leoniceps*: the greater disparity in size between the dentary and the other bones of the jaw, and the absence of the elongation of the condylar surface which is so conspicuous a feature in *D. leoniceps*.

The *articular* is continued forwards on the lower side of the inner surface of the ramus. Its anterior end is a delicate lamella concealed from view by the splenial. This is the same arrangement as in *D. leoniceps*, and no doubt accounts for a statement made by one observer that the splenial runs along its whole length.

In the region of the vacuity, and also for some distance in front of it, the *surangular* is a rod-like bone—flat on its inner side, semi-cylindrical on its outer side—which fits loosely in a groove on the inner surface of the dentary. This groove is widely open for the greater part of its length, but at its extreme anterior end its upper margin is prolonged downwards over the inner surface of the surangular, so that this latter bone at its tip is almost completely surrounded by the dentary. Behind the vacuity of the lower jaw the surangular is produced downwards and meets the forward continuation of the articular on the inner side of the ramus.

On the outer side of the ramus the *angular* forms the lower boundary of the vacuity. Posteriorly this bone increases in height and so forms the posterior boundary of the vacuity on the outer surface. The anterior end of the angular is wedged in between the dentary on the outside and the splenial on the inside.

The *dentary*: the contrast between this massive bone and the delicate and in part almost laminar bones connected with it is very marked. WATSON has pointed out a similar disproportion in the jaws of Cynodonts and has made some interesting suggestions concerning it.\*

The way in which the surangular is connected with the dentary rather suggests that there may have been some sliding action of the bones upon one another.

The dentary is here proportionately much larger than in *Dicynodon leoniceps*, being three times as long as the part of the jaw behind it, whereas in *D. leoniceps*

\* D. M. S. WATSON, "On some Reptilian Lower Jaws," 'Ann. and Mag. Nat. Hist.,' Ser. 8, vol. 10, p. 581 (1912).



the proportion is 2 : 1. As in that species, the dentaries are indistinguishably fused at the symphysis, which is a long one. The great elongation of the condyle, which we described in our previous specimen, with the suggestion that it was intended to permit of a sliding motion of the condyle in its socket, is absent in the present one. The tusks being absent, a wide gape was no longer necessary.

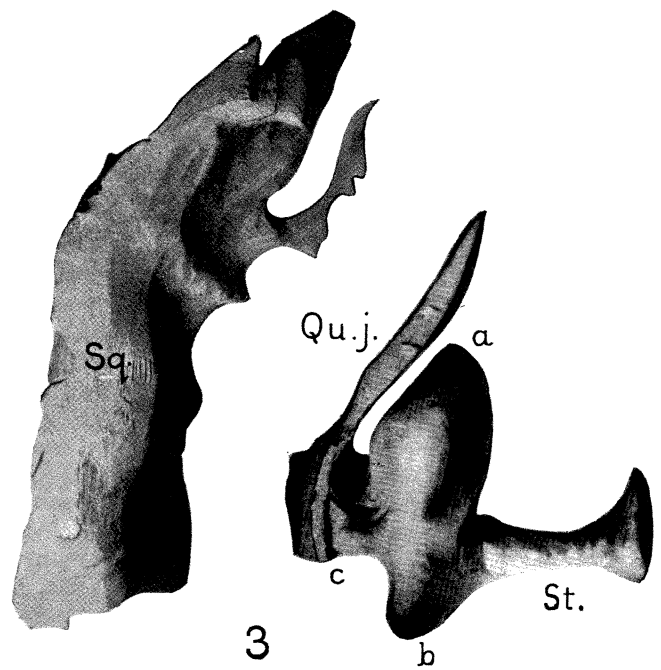
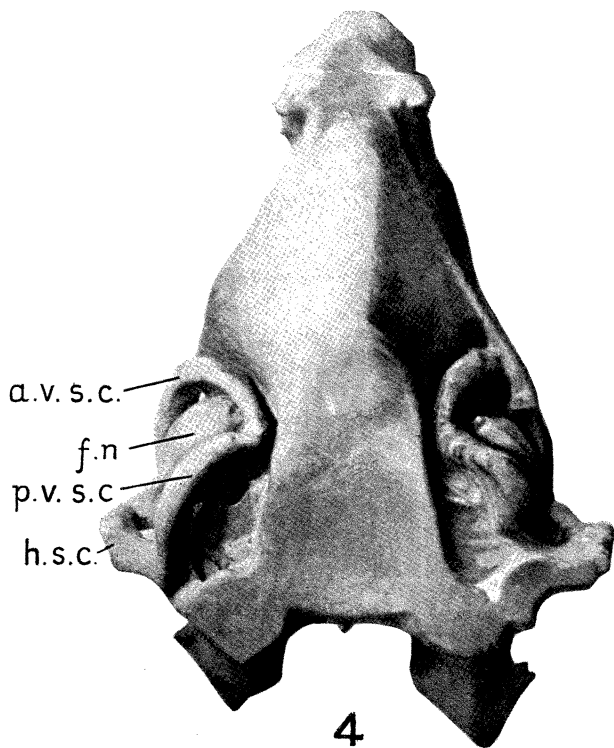
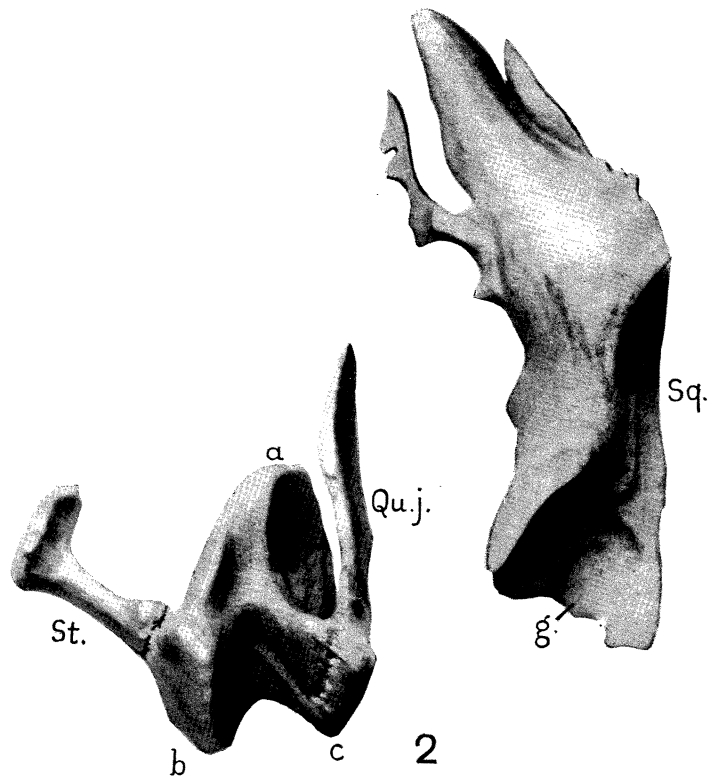
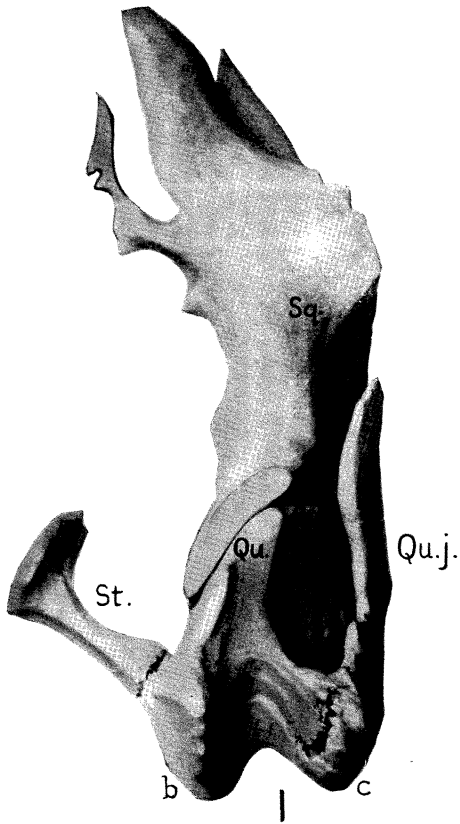
When the jaw is closed the pterygoids project downwards between the rami of the jaw—a feature which is present also in *D. leoniceps*, though we had not noticed it at the time when we wrote our description of that skull. As the pterygoids bear ventrally sharp ridges it might be thought at a first glance that they played some part in mastication. It is more probable that the ridges mark the boundaries of the surface of origin of masticatory muscles, possibly the same muscle which we have suggested had part of its origin on the surface of the dental chamber (p. 535).

*Skeleton of the Sense Organs.*—Owing to the imperfection of the anterior end of the skull it is impossible to say whether septomaxillary bones were present or not.

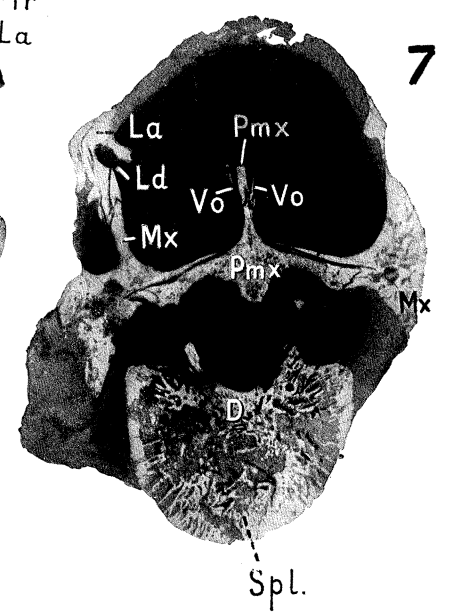
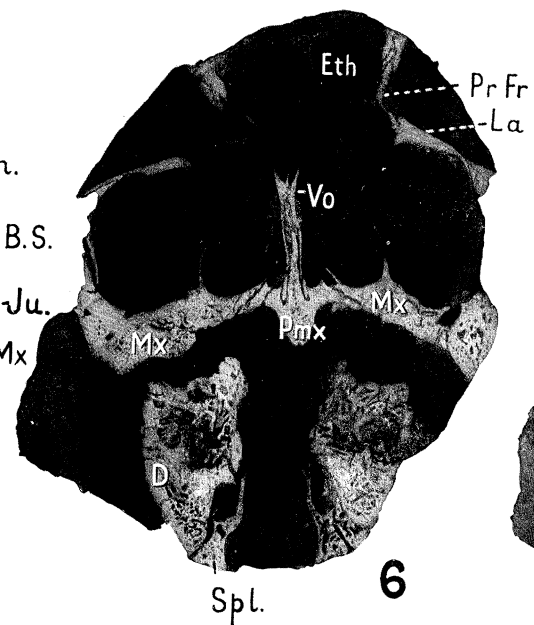
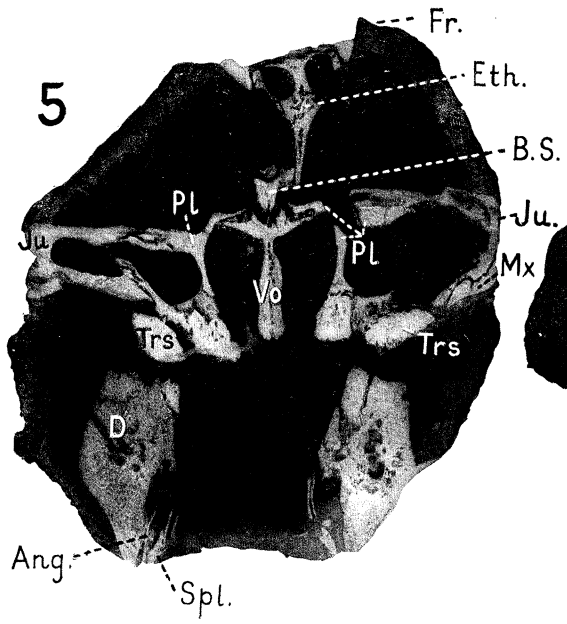
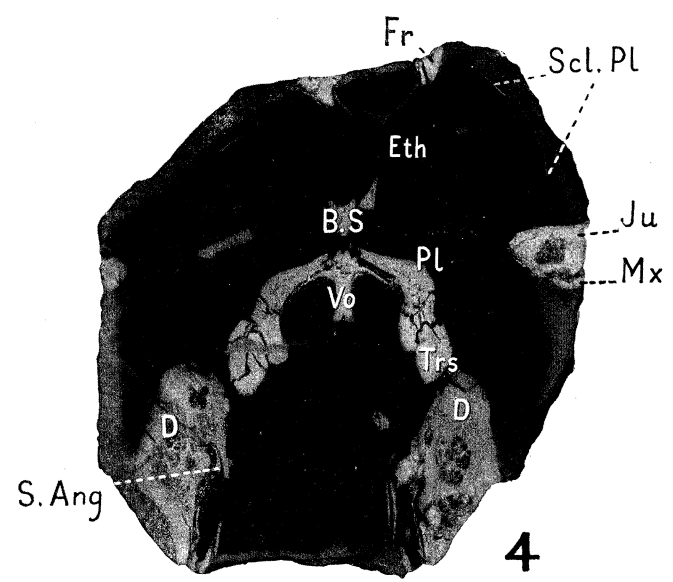
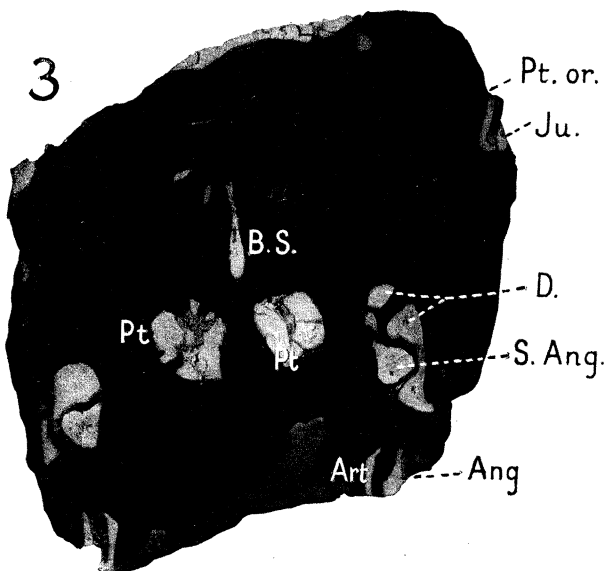
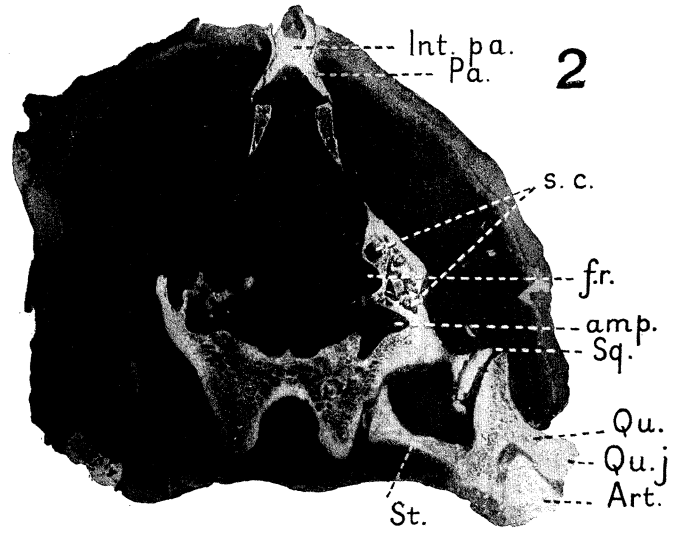
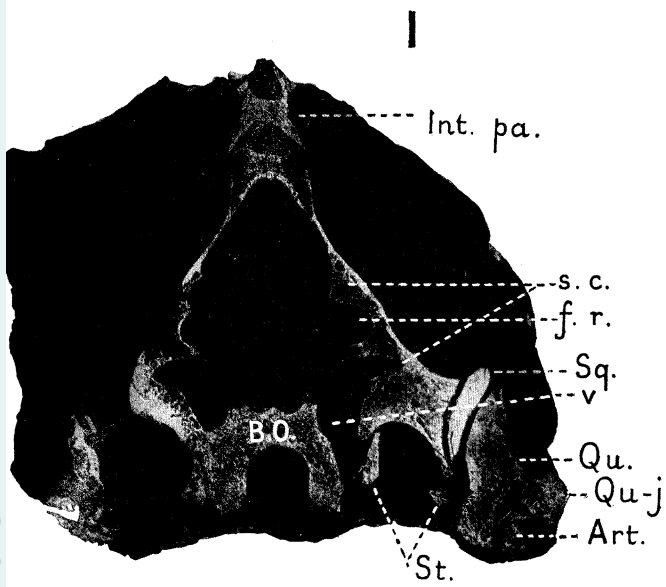
In the orbits sclerotic plates are clearly present in their natural position, but on neither side is a complete ring preserved. HUXLEY noticed these in 1859 in *Dicynodon Murrayi*, but as far as we are aware they have not been described since in any Dicynodont genus.

The model of the skull cavity with the canals of the ear (Plate 35) shows very well marked floccular lobes. It was necessary to make the model of the ear canals in this way because of their incomplete separation by bony partition from the skull cavity—a point in which this specimen differs from *D. leoniceps*.

*Note:* *May*, 1916.—This paper was ready for publication in its present form at the end of 1913, but was delayed for presentation owing to unforeseen circumstances. This will explain the absence of any reference to the more recent literature of the subject, especially a paper by Messrs. W. K. GREGORY and L. A. ADAMS, “On the Temporal Fossæ of Vertebrates in Relation to the Jaw Muscles” (‘Science,’ N.S., vol. 41, p. 763, 1915), in which the same explanation as we have proposed to account for certain vacuities (p. 535) is applied to the temporal fenestræ of the skull.



PHILOSOPHICAL TRANSACTIONS OF THE ROYAL SOCIETY OF BIOLOGICAL SCIENCES



## DESCRIPTION OF PLATES.

## ABBREVIATIONS USED.

A. b. c. . . .	Processes of the quadrate.	Pa. . . . .	Parietal.
Amp. . . . .	Ampulla.	P. v. s. c. . . .	Posterior vertical semicircular canal.
Ang. . . . .	Angular.	Pl. . . . .	Palatine.
Art. . . . .	Articular.	Pmx. . . . .	Premaxilla.
A. v. s. c. . . .	Anterior vertical semicir- cular canal.	Pr. Fr. . . . .	Prefrontal.
B. O. . . . .	Basi-occipital.	Pt. . . . .	Pterygoid.
B. S. . . . .	Basi-sphenoid.	Pt. or. . . . .	Post-orbital.
D. . . . .	Dentary.	Qu. . . . .	Quadrate.
Eth. . . . .	Ethmoid	Qu.-j. . . . .	Quadrato-jugal.
F.r. . . . .	Floccular recess.	S. ang. . . . .	Surangular.
Fr. . . . .	Frontal.	S. c. . . . .	Semicircular canal of ear.
G. . . . .	Groove for quadrate on squamosal.	Scl. Pl. . . . .	Sclerotic plate.
H. s. c. . . . .	Horizontal semicircular canal.	Spl. . . . .	Splenic.
Int. pa. . . . .	Interparietal.	Sq. . . . .	Squamosal.
Ju. . . . .	Jugal.	St. . . . .	Stapes.
La. . . . .	Lachrymal.	Trs. . . . .	Transverse.
L. d. . . . .	Lachrymal duct.	V. . . . .	Vestibule.
Mx. . . . .	Maxilla.	Vo. . . . .	Vomer.

## PLATE 35.

Reconstructions of part of the posterior region of the skull and cranial cavity with the aural canals.

## PLATE 36.

Transverse sections of the skull. The skull was cut at approximately regular intervals, measuring 0.413 mm. on the average. The total number of sections was 133; the figures (1 to 7) are numbered in order from behind forwards, and represent the following sections respectively: fig. 1, Section 109; fig. 2, Section 107; fig. 3, Section 74; fig. 4, Section 52; fig. 5, Section 47; fig. 6, Section 36; fig. 7, Section 28.

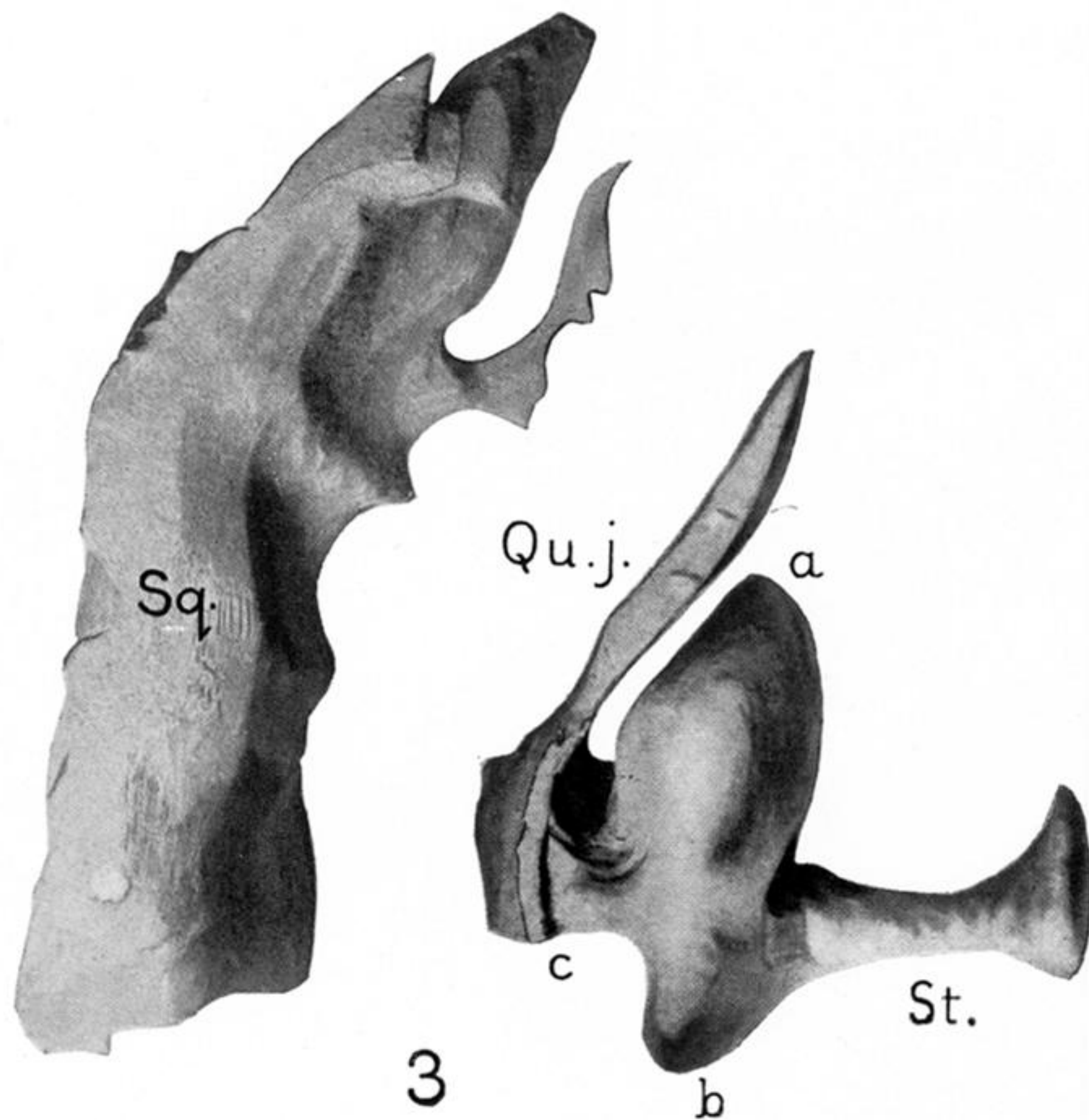
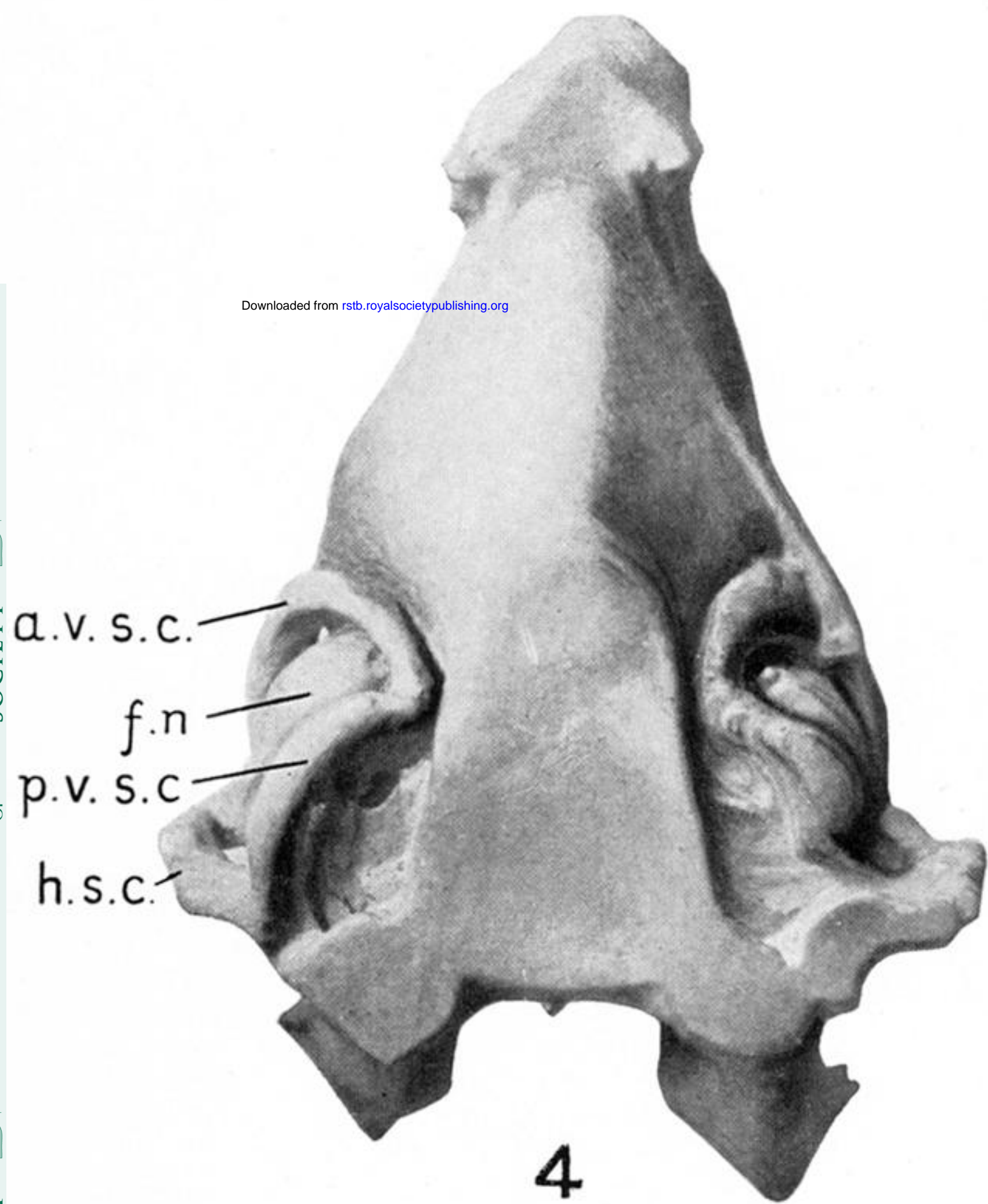
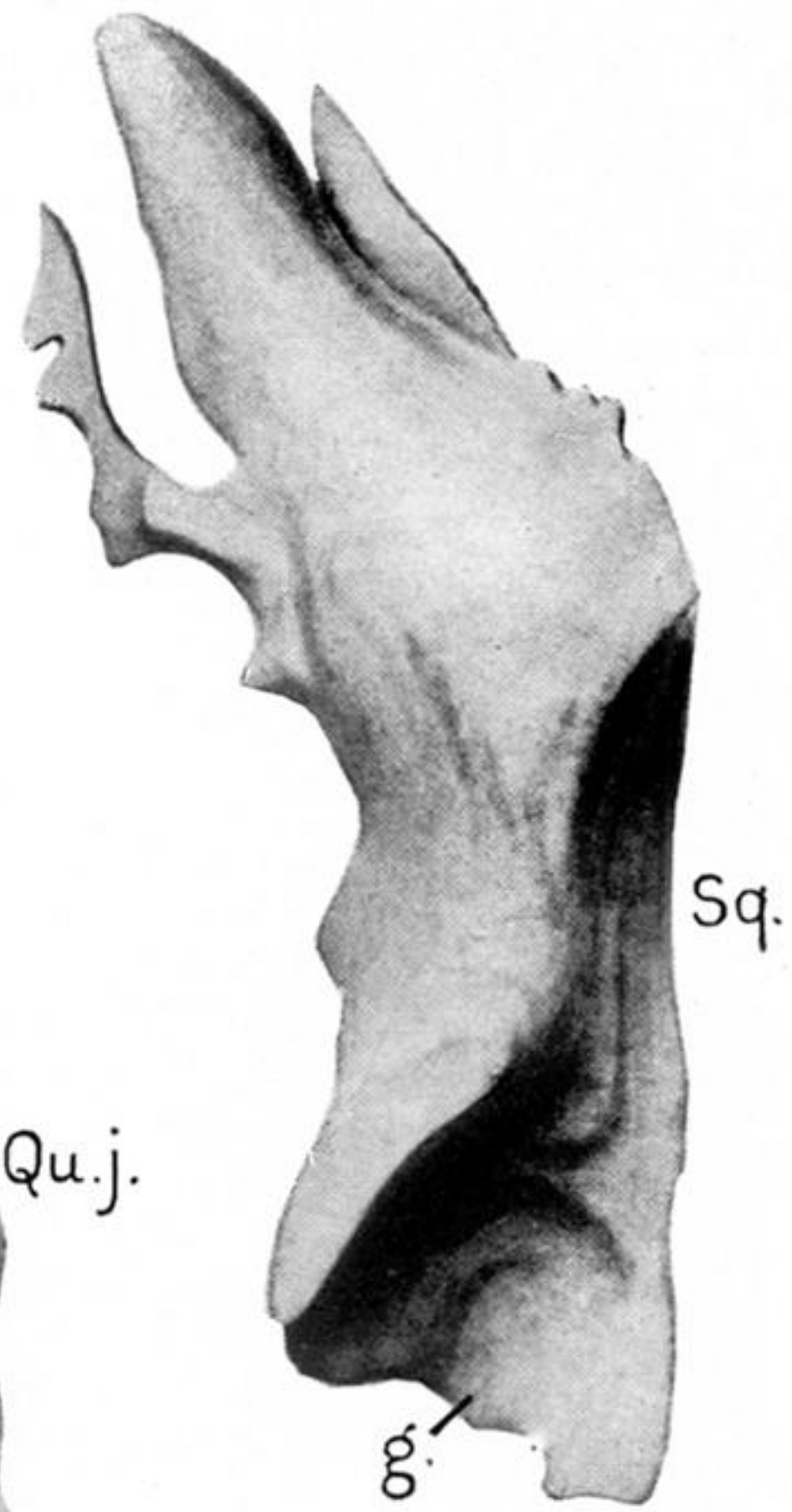
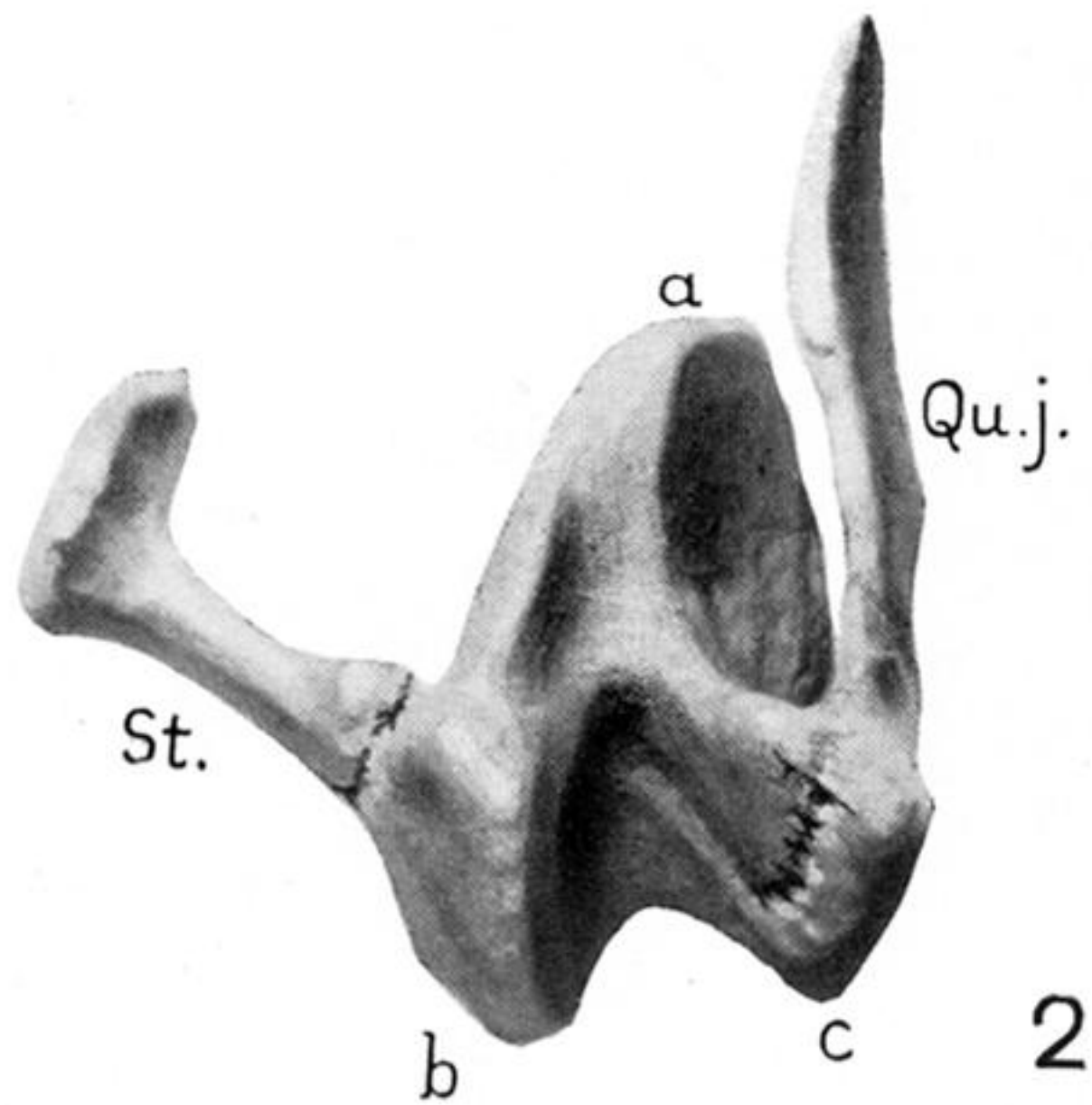
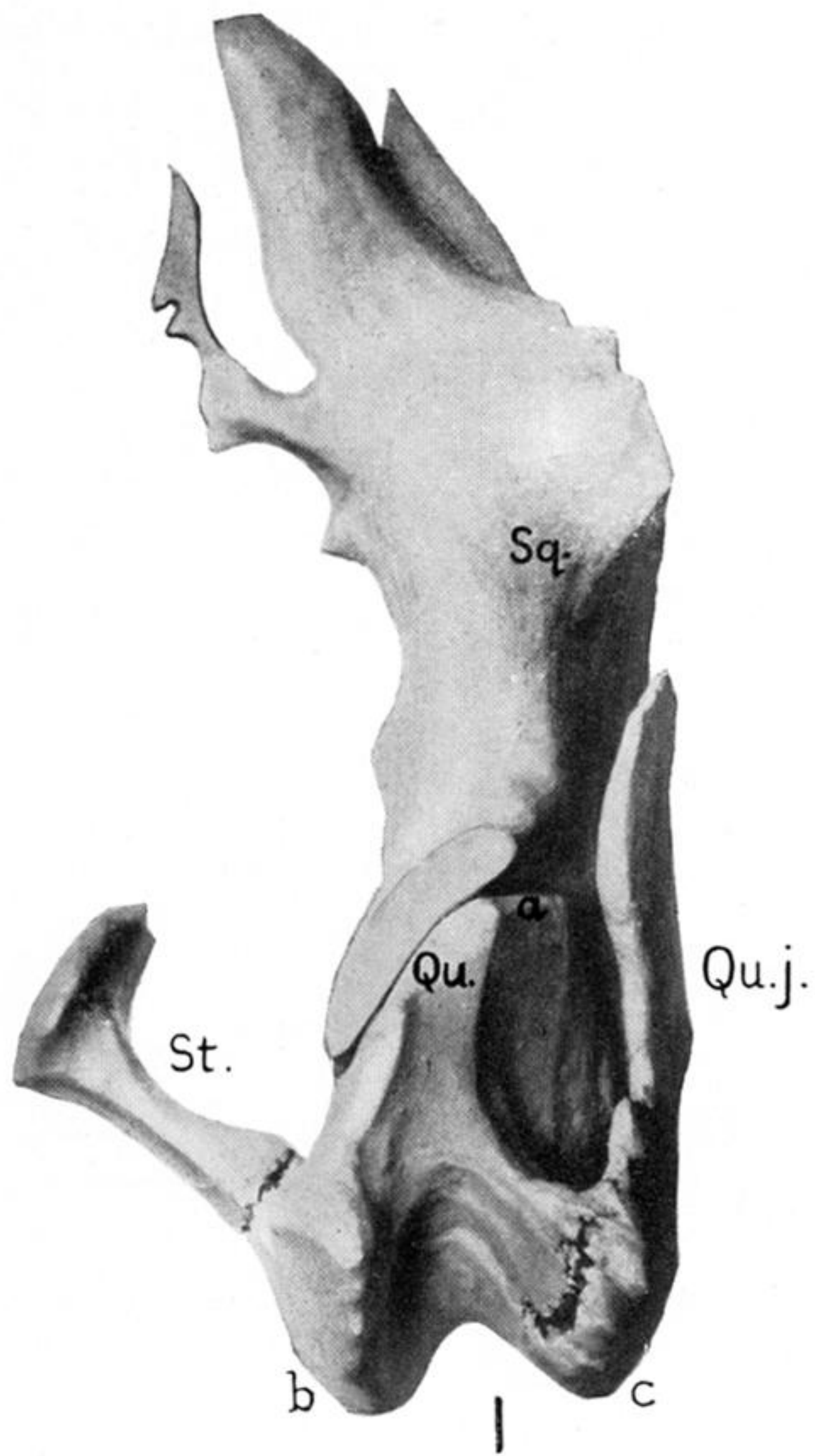


PLATE 35.

Reconstructions of part of the posterior region of the skull and cranial cavity with the aural canals.

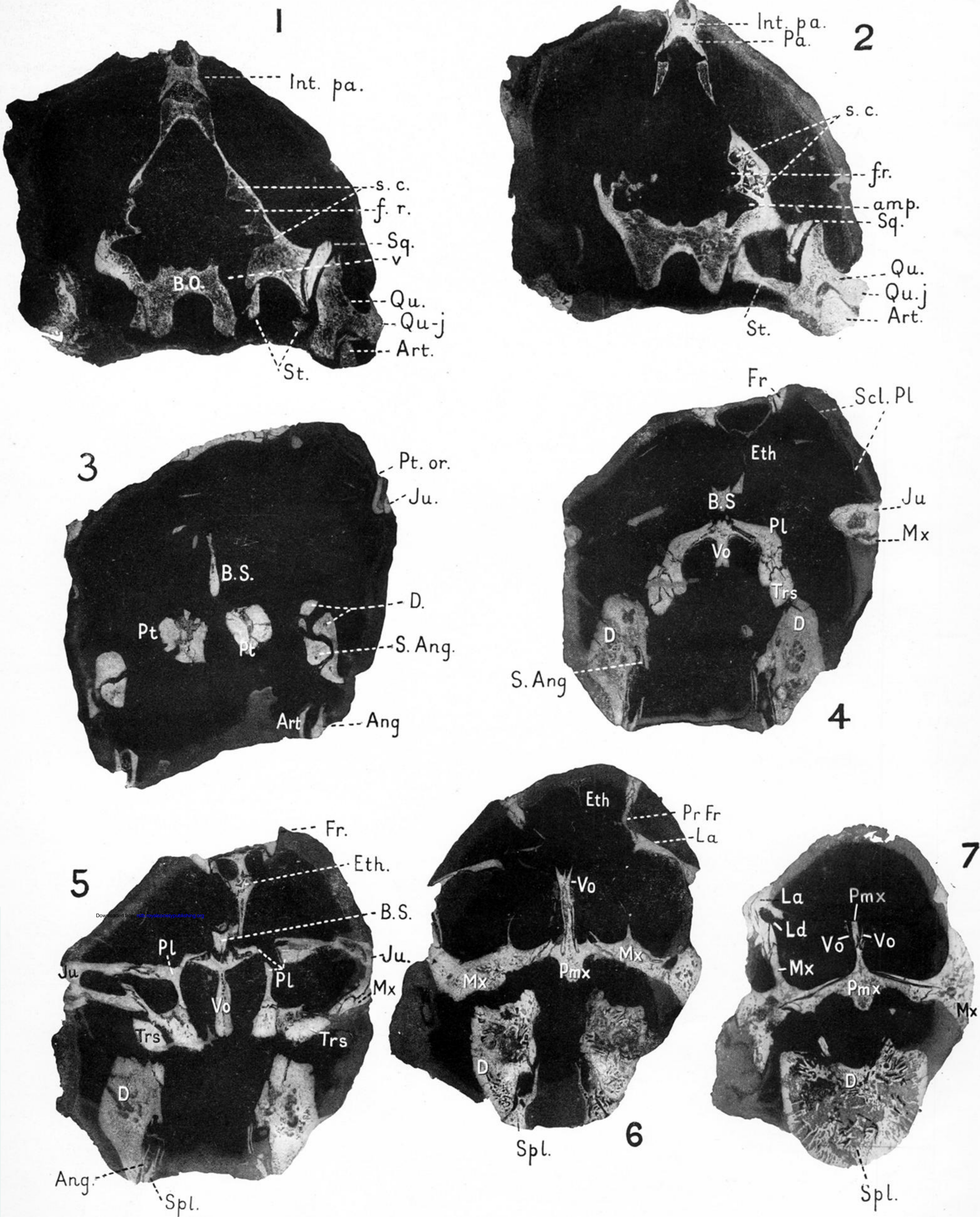


PLATE 36.

Transverse sections of the skull. The skull was cut at approximately regular intervals, measuring 0.413 mm. on the average. The total number of sections was 133; the figures (1 to 7) are numbered in order from behind forwards, and represent the following sections respectively: fig. 1, Section 109; fig. 2, Section 107; fig. 3, Section 74; fig. 4, Section 52; fig. 5, Section 47; fig. 6, Section 36; fig. 7, Section 28.